

Background

Luxembourg is a country with five different hospitals and a single public Pathology Laboratory, the Laboratoire National de Santé (LNS). This geographic separation poses challenges, the most notable of which is long delays in the pathologic intraoperative frozen section reporting process, since the fresh samples have to be sent to the LNS. (Fig 1)

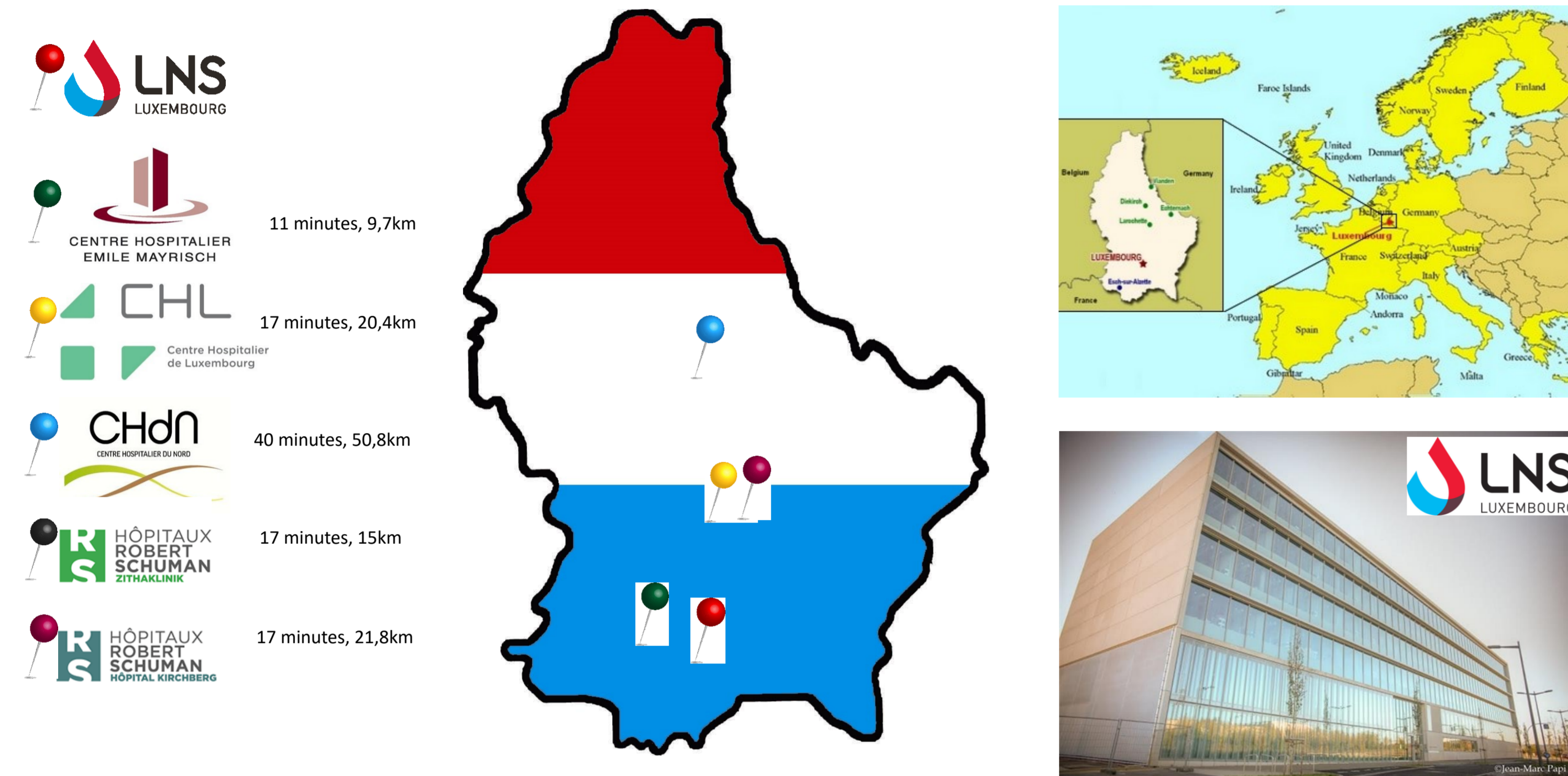


Fig 1. Average transportation time from the 5 different hospitals to the Laboratoire National de Santé (LNS) by road (non-rush hour) as estimated by google maps.

Methods

An integrative Telepathology project was conceived during 2015 in order to solve the delay in intraoperative frozen section reporting for all the hospitals in Luxembourg. A histopathology technician is to be permanently stationed at each of the hospitals, and perform the registration, macroscopic dissection and histologic frozen slides of the intraoperative (and other) specimens. During non intraoperative procedures, sampling of non-frozen specimens is to be performed.

A Telepathology room was accommodated in two hospitals (Centre Hospitalier Emile Mayrisch-CHEM and Centre Hospitalier de Luxembourg-CHL) during 2016 and 2017, with a plan to expand to the remaining three hospitals. Each room was equipped with a Macroscopic dissection table (Workstation Bx, MILESTONE) with an integrated Macroscopic Camera (Macro Path Pro-X, MILESTONE), a Cryo-embedder (PrestoCHILL, MILESTONE), a Cryostat (Leica CM1520), a Small Linear Stainer (Leica ST 4020) and a remote controlled microscope (VisionTEK Live Digital Microscope, SAKURA). (Fig. 2)

A protected virtual private network (VPN) network was established between institutions to allow a live view and communication of both macro and micro images. A validation phase of twenty cases per hospital was established and a follow up until March 2018 was further analyzed.

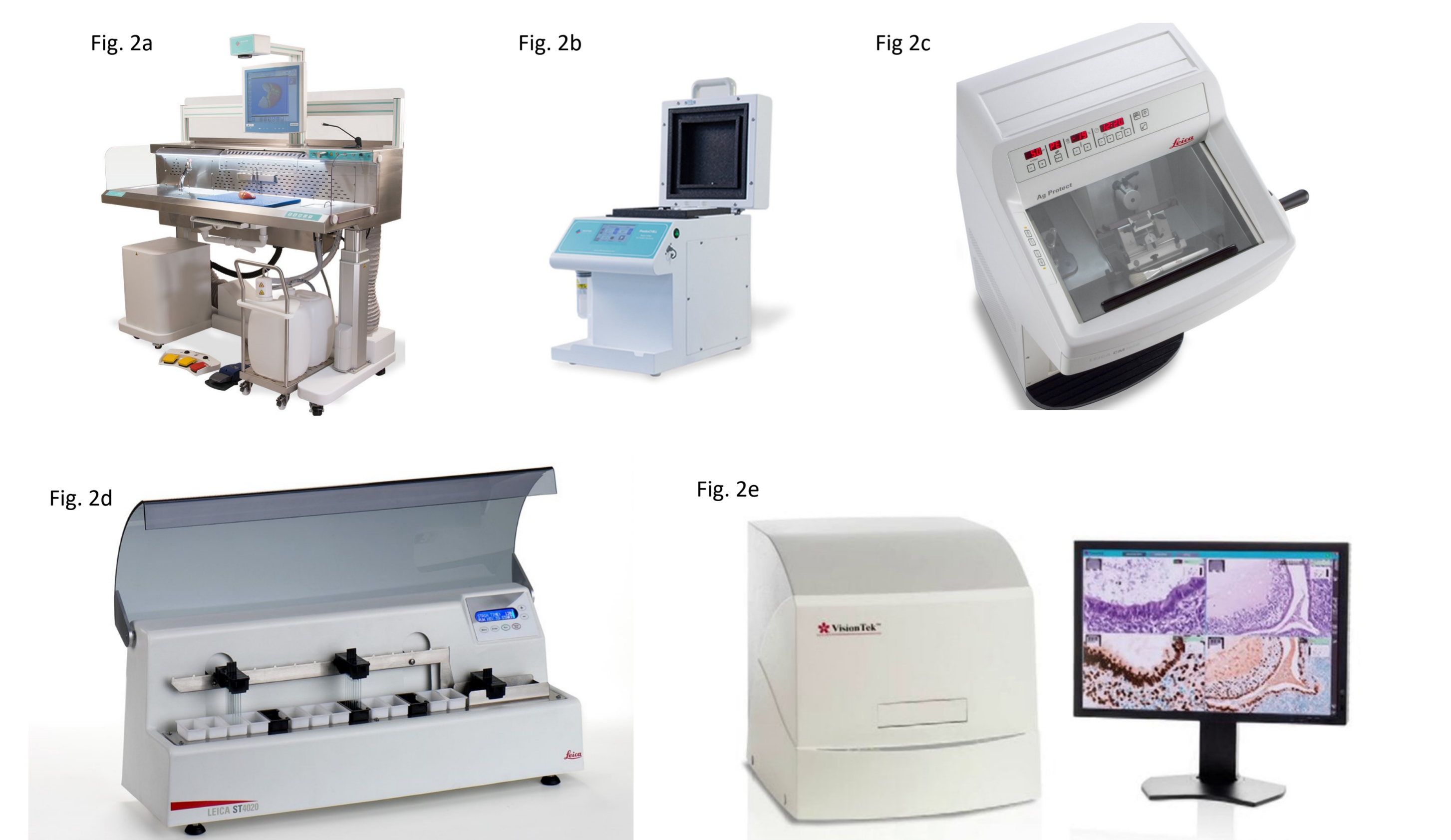

Fig 2. a) Macroscopic dissection table (Workstation Bx, MILESTONE) with an integrated Macroscopic Camera (Macro Path Pro-X, MILESTONE) b) Cryo-embedder (PrestoCHILL, MILESTONE), c) Cryostat (Leica CM1520), d) Small Linear Stainer (Leica ST 4020), e) remote controlled microscope (VisionTEK Live Digital Microscope, SAKURA). (Fig. 2)

Bibliography

Intraoperative pathology consultation: error, cause and impact. Etienne Mahe, Shamim Ara, Mona Bishara, Annie Kurian, Syeda Tauqir, Nafisa Ursani, Pooja Vasudev, Tariq Aziz, Cathy Ross, Alice Lytwyn Can J Surg. 2013 Jun; 56(3): E13E18. doi: 10.1503/cjs.011112

Telepathology Impacts and Implementation Challenges: A Scoping Review. Meyer J, Paré G. Arch Pathol Lab Med. 2015 Dec;139(12):1550-7. doi: 10.5858/arpa.2014-0606-RA. Review. PubMed PMID: 26619028.

Overview of Telepathology. Farahani, Navid & Pantanowitz, Liron. (2015). Surgical Pathology Clinics. 8. 10.1016/j.path.2015.02.018.

Results

Comparison of delays prior to the use of Telepathology showed a clear reduced time in frozen section reporting (average of 15 and 20 minutes from CHEM and CHL respectively).

Discrepancies between virtual and traditional frozen section were analyzed, with no significant disadvantages of a telepathology assessment Vs a traditional one.

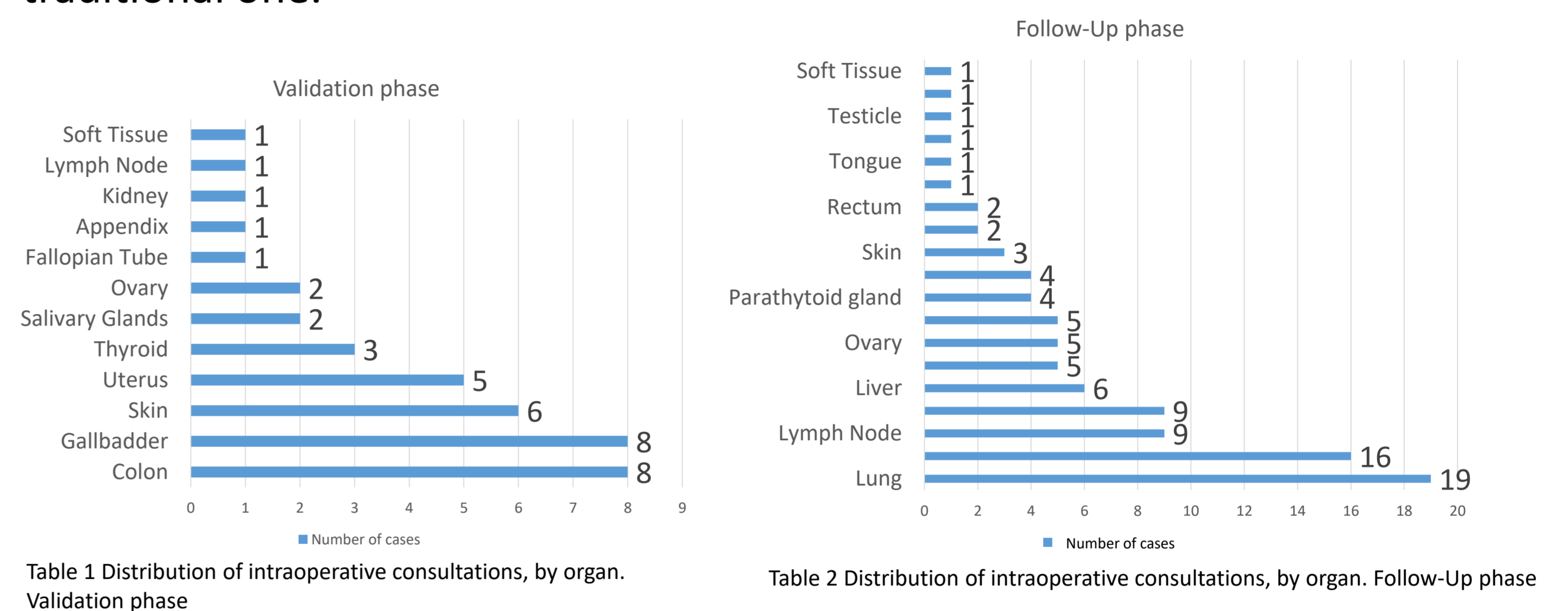


Table 1 Distribution of intraoperative consultations, by organ. Validation phase

Table 2 Distribution of intraoperative consultations, by organ. Follow-Up phase

During the validation phase a total of 40 cases (20 per institution) belonging to 40 different patients were performed. (Table 1). Two discordant cases, with a category change, were identified, both due to the sampling process. One in a non-oriented salivary gland with a 3mm pleomorphic adenoma, and one micropapillary carcinoma in a thyroid specimen. After analysis, it was determined by three pathologists (DV, JA, AC) that the fact that the cases were reported remotely had no impact on said discrepancies.

During the follow-up phase a total of 95 cases belonging to 90 different patients were performed (Table 2). One case was deferred for diagnosis in the formalin fixed paraffin embedded (FFPE) sample, while 6 cases showed discrepancies between the intraoperative assessment versus the final diagnosis. In 3 of them, the sampling process failed to include the lesions or diagnostic key areas (micropapillary carcinoma of the thyroid, non invasive follicular thyroid neoplasia with papillary-like nuclear features (NIFTP) and a residual rectal adenocarcinoma after radio-chemotherapy). In the other 3, an interpretation discrepancy was identified (a non-small cell carcinoma of the lung was reclassified as carcinoid tumor of the lung; an inflammatory process of the soft tissue was reclassified as a granular cell tumor; and a lymph node in a parathyroid surgery was reported as non-malignant and later reclassified as a lymphocytic lymphoma) (See table 3) Again, after discussion by three pathologists (DV, JA, AC) it was determined that the fact that these cases were reported remotely had no influence on said discrepancies.

Organ	Frozen section diagnosis	Permanent diagnosis	Discrepancy type
Thyroid	Follicular lesion	NIFTP	Sampling
Lung	Non-small cell carcinoma	Carcinoid tumor	Interpretation
Rectum (post-chemo and radio therapy)	No evidence of malignancy	Residual carcinoma	Sampling
Thyroid	Benign (Goiter)	Micropapillary carcinoma	Sampling
Soft Tissue	Inflammation	Granular cell tumor	Interpretation
Parathyroid (lymph node)	No evidence of malignancy	Lymphocytic lymphoma	Interpretation

Table 3 Discordant cases in the Follow-Up phase

Conclusions

A project to integrate all the hospitals in Luxembourg with a central Pathology Laboratory is underway. Two of the hospitals have been already integrated and as of May 2018, the test phase in a third one (Centre Hospitalier du Nord-CHdN) has been completed. Its impact on patient care and surgeon satisfaction has proved beneficial due to:

- 1) reduced time in frozen section reporting
- 2) improved communication regarding macroscopic assessment allowing the surgeon to indicate the areas of interest (live mode)
- 3) optimal frozen sections due to immediate freezing and sample not subject to drying effect in long transportations (Fig 3).

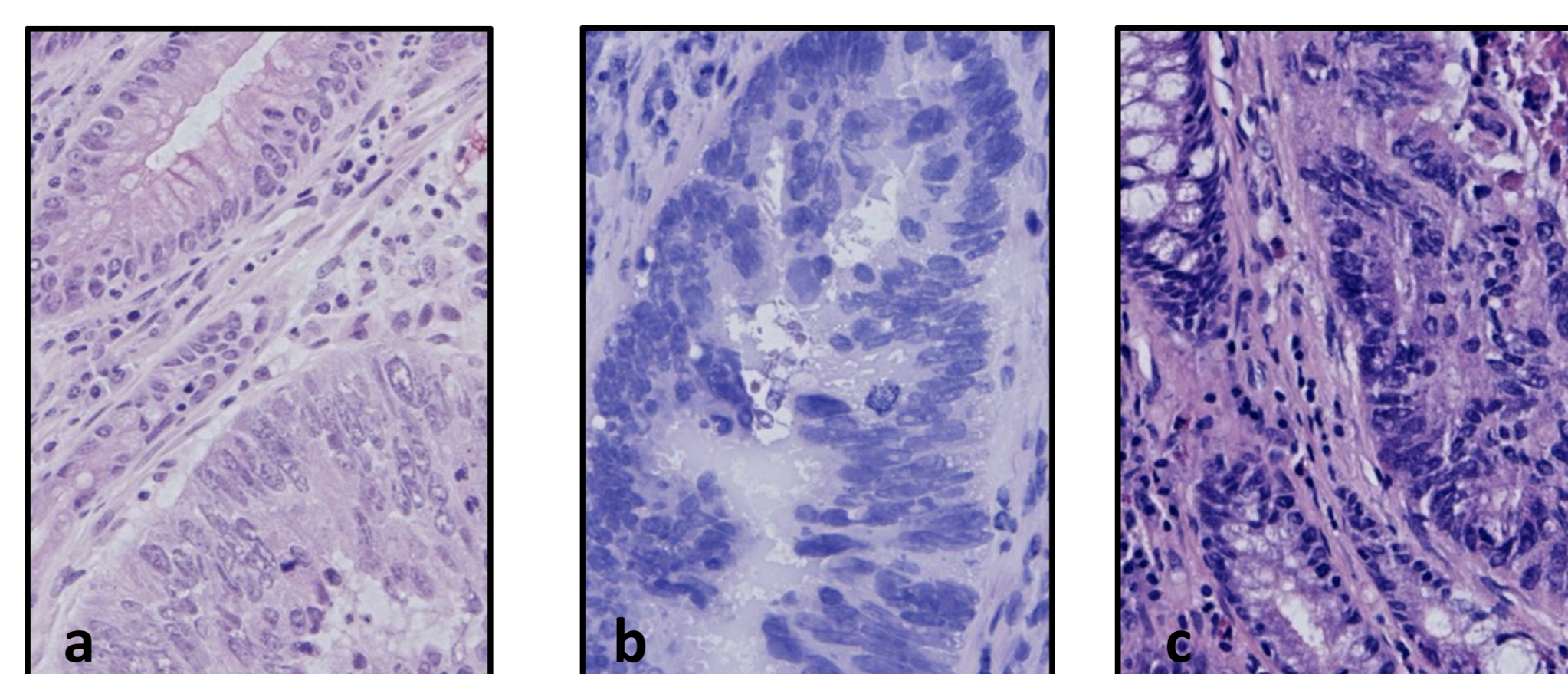


Fig 3
a) Frozen section, telepathology image
b) Frozen section, LNS
c) Formalin fixed tissue